




Aydın Dental Journal

Journal homepage: <http://dergipark.ulakbim.gov.tr/adj>



FOCAL EPITHELIAL HYPERPLASIA (HECK'S DISEASE) TREATED WITH USING A DIODE LASER

DergiPark
AKADEMİK

Murat ÖZLE¹, Sercan KÜÇÜKKURT², Gizem DİMİLİLER¹, Burcu SENGUVEN³, Sedat ÇETİNER¹

ABSTRACT

Focal epithelial hyperplasia (FEH) or Heck's disease is an uncommon asymptomatic proliferation of oral mucosa. It usually presents with multiple asymptomatic and occasionally painful exophytic papules or nodules on the buccal mucosa, gingiva, tongue or lips. Although the lesions may resolve after months or years with or without any specific treatment, they may also indefinitely persist or frequently recur. These lesions can be surgically removed if the lesions are exposed to occlusal trauma or the patient has aesthetic concerns. A 35-year-old female patient was admitted to our clinic with the complaint of multiple nodules on her lip and buccal mucosa. After an intraoral examination, we detected multiple, soft, pink, non-inflammatory, and exophytic 2 to 8 mm papules on the oral mucosa including buccal mucosa and lower lip. Histopathologic examination of the incisional biopsy of a papule confirmed the diagnosis of focal epithelial hyperplasia. Oral lesions were treated with serial partial excisions using diode laser. After 24 months of a follow-up period, there were no signs of recurrence. Although Heck's disease is generally seen in childhood and adolescence, a rare case of FEH seen in a female adult patient who has got treatment with diode laser and 24 months of follow-up.

Keywords: *Focal Epithelial Hyperplasia, Heck's Disease, Human Papillomavirus (HPV), Diode Laser.*

ÖZET

Fokal epitelyal hiperplazi (FEH) veya Heck hastalığı, oral mukozanın nadir görülen, asemptomatik bir proliferasyonudur. Genellikle bukkal mukoza, gingiva, dilde veya dudaklarda birden fazla sayıda, çoğu zaman asemptomatik ancak zaman zaman ağrılı ekzofitik papüller veya nodüller olarak görülür. Lezyonlar herhangi bir tedaviye bağlı olarak ya da olmadan aylar ya da yıllar içerisinde düzelebilseler de, süresiz olarak devam edebilir ya da sık sık tekrarlanabilirler. Bu lezyonların, oklüzal travmaya maruz kalacağına karar verilirse veya hastada estetik endişelere neden olursa cerrahi olarak çıkarılabilirler. Kliniğimize 35 yaşında bir kadın hasta, dudağı ve bukkal mukozasında birden fazla nodül yakınması ile başvurdu. Ağız içi muayenesinde, sol bukkal mukoza ve alt dudak olmak üzere çoklu, yumuşak, pembe, inflamatuvar, ekzofitik, 2-8 mm'lik papüller görüldü. Papüllerden birinin eksizyonel biyopsisinin histopatolojik incelemesi FEH tanısını teyit etti. Teşhis konulmasının ardından oral lezyonlar, diyot lazer kullanılarak seri eksizyonlarla tedavi edildi. 24 aylık takip sonrasında nüks bulgularına rastlanmamıştır. FEH büyük oranda çocukluk ve ergenlik döneminde görülen bir hastalık olmasına rağmen, bu vaka raporunda, erişkin bir kadın hastada teşhis edilen FEH, diode lazer ile tedavi edilip ve izleyen 24 aylık süreçte takibi yapılmıştır.

Anahtar Kelimeler: *Fokal Epitelyal Hiperplazi, Heck Hastalığı, İnsan İpapillomavirüs (HPV), Diode Lazer*

¹ Gazi Üniversitesi Diş Hekimliği Fakültesi, Ağız, Diş ve Çene Cerrahisi, ABD

² İstanbul Aydın Üniversitesi Diş Hekimliği Fakültesi, Ağız, Diş ve Çene Cerrahisi, ABD

³ Gazi Üniversitesi Diş Hekimliği Fakültesi, Oral Patoloji, ABD

INTRODUCTION

Focal epithelial hyperplasia (FEH) or Heck's disease is a rare asymptomatic proliferation of oral mucosa, which was first diagnosed by Archard and Heck in 1965 in the Native American population.¹ The incidence of the disease ranges from 0.002% to 35% depending on the population and the investigated geographical area.² It affects mostly children and young adults regardless gender difference.³ Recently, FEH has been also described as multifocal papillomavirus epithelial hyperplasia.⁴

Focal papillomavirus epithelial hyperplasia is strongly associated with human papilloma virus (HPV) infection; DNA of HPV was detected in 80.3% of FEH lesions.⁵ The etiologic agent of FEH was first described in 1983, as HPV 13 related to HPV 6 and HPV 11.⁶ In the following years, another HPV strain was isolated from FEH and similarly named as HPV 32 in relation to HPV 6 and HPV 13.⁷

Although the diagnosis of FEH can sometimes be made by clinical examination, ethnicity and social anamnesis, the biopsy is still the gold standard for definitive diagnosis.⁸ In the diagnosis, histological evaluation is important and it allows the identification of the characteristics of lesion such as hyperparakeratosis, acanthosis, elongation and anastomosis of the rete ridges, classical koilocyte, perinuclear cytoplasmic halos and nuclear dysplasia.⁹⁻¹¹ FEH is usually detected clinically as exophytic soft papules or nodules in the gingiva, tongue or lips in the same color as the neighboring healthy mucosa, and mostly asymptomatic but rarely painful, smoothly restricted on the cheek mucosa.^{9, 12-14}

Lesions may recover within months or years

without requiring any treatment, but some cases may not improve and recur repeatedly. Nevertheless, FEH has a benign nature. For this reason, it may not always require treatment. However, exophytic lesions can be surgically removed because of an occlusal trauma or aesthetic concerns.^{3, 9}

This study reports a case of focal epithelial hyperplasia in a middle-aged Turkish woman, which occurred on her lips and cheek mucosa, and its treatment with diode laser excision and her 24 months of follow-up.

CASE REPORT

A 35-year-old female patient was admitted to our department with the diagnosis of multiple nodules on her lips and buccal mucosa. The patient reported that painless and soft consistency lesions has been spontaneously developed about two years ago. According to the anamnesis, the patient had no systemic disease other than oral complaints, and no history of allergies or hereditary disease. Moreover, the patient stated that no one from her close family members have had similar oral lesions

Since such oral lesions may be oral symptoms of HIV infection, additional laboratory tests have been required in order to detect and eliminate the HIV infection and other sexually transmitted diseases. According to test results, patient's routine blood tests were within the normal limits. Anti-HIV, VDRL and FT-ABS tests were negative, however only Anti-HBc IgG and Anti-HBs tests were positive.

Intraoral examination revealed multiple, soft, pink, inflammatory, exophytic, 2-8 mm papules on the left buccal mucosa (Fig. 1). Radiographic examination revealed that there

was no hard tissue involved in the lesion area.

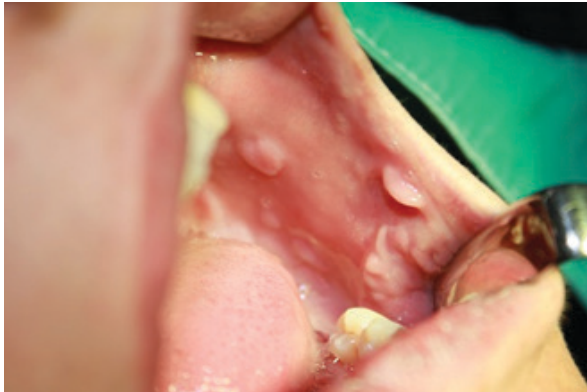


Figure 1. Pre-operative intraoral image of the patient

Under local anesthesia, a few of the lesions were removed by excisional biopsy with the help of scalpel in order to distinguish the lesions from other similar pathological lesions. In order to protect the wounded areas from infection, the patient was prescribed a mouthwash containing 0.12% chlorhexidine that should be used 3 three times a day. After the excisional biopsy, postoperative proposals were made.

Biopsy specimen with dimensions between 1 and 3 mm was sent to Gazi University, Faculty of Dentistry, Department of Oral Pathology. Specimens were embedded in paraffin after the routine procedures and sections had been taken with a microtome and with a thickness of $0,5\mu$ and then, stained with Hematoxylin-Eosin (H&E) and examined under light microscope. In the histological examination, we detected oral epithelium and acanthosis in the confusion. Furthermore, areas with coilocitas cells and cells with mitotic-like nuclear degeneration (mitosoid cells) were observed. The basal layer was not damaged and chronic inflammatory infiltration has been found in the connective tissue. Based on the

clinical and histopathologic features, a clinical diagnosis of FEH was made.

Oral lesions were treated with serial partial excision using diode laser. (Fig. 2) The diode laser was applied with excitation wavelengths of 810 nm, 4.0 W power, 0.5 MS continuous wave and 1000 Hz frequency power.

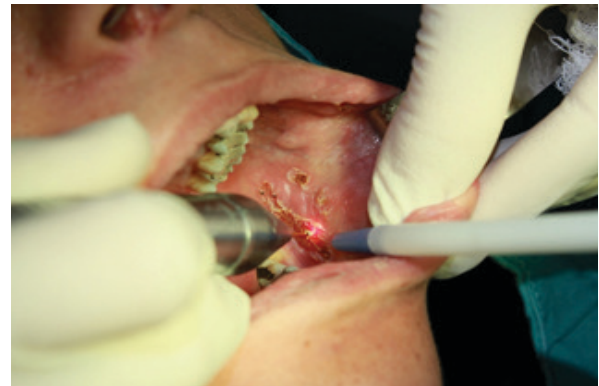

Figure 2. Excision of the lesion with diode laser

No suture was applied after the excision and the area was left for secondary healing (Fig. 3)

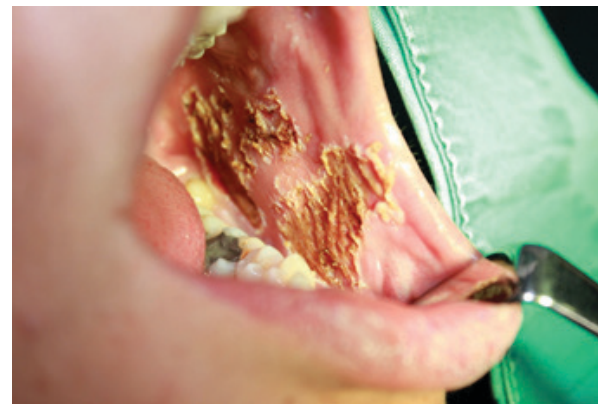

Figure 3. Post-operative Image

No complications were observed during a routine follow up period following the healing period. No recurrence occurred after 24 months of follow-up (Fig. 4).

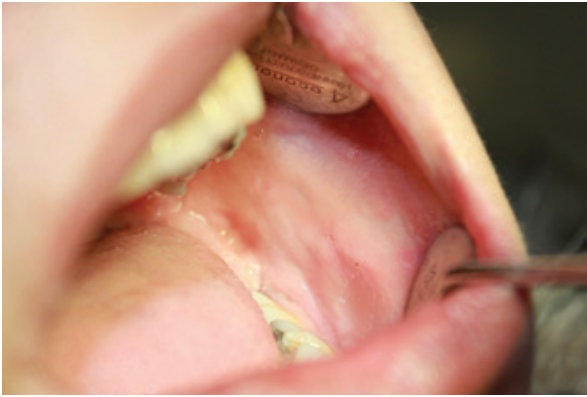

Figure 4. Intraoral image after 24 months

DISCUSSION

HPV is a type of virus that infects skin and mucous membranes and can induce the formation of both benign and malignant tumors. Infection begins when the virus enters the host from micro-breaks.¹⁰ FEH is a benign infectious disease caused by HPV and its symptoms can be only seen in the mouth. FEH is most commonly found in Eskimos, North and Central American Indians.^{9,12} In addition, various cases have been reported among some ethnic groups in the countries such as Spain, Netherlands, Brazil, South Africa, and in Turkey.^{2,3,15}

The correct diagnosis is achieved by screening other benign oral and oropharyngeal lesions associated with HPV, such as squamous cell papilloma, condyloma acuminata, common warts and malignant oral lesions, especially squamous cell carcinoma.¹⁰ Diagnosis can be made based on the clinical, histological and cytological features of the lesions and can be supported by immunohistochemical assays

which detect the presence of HPV types 13 and 32, molecular biological tests such as in situ hybridization, Southern blot and PCR (Polymerase chain reaction).¹⁶ Although the etiology of FEH is associated with a virus, it is considered to be a genetic predisposition because it is a well-known trend in some ethnic groups.^{11,13,15} In our case, the possibility of genetic transmission was not taken into account because no other case could be identified in the family and the ethnic origin of the family was not one of the trending origins.

Major histologic features of FEH include epidermal acanthosis and parakeratosis, thickening and extension of rete ridges, and marked koilocytosis with characteristic mitosoid numbers.¹⁷ These lesions may persist for a few years, but they do not become malignant and most tend to regress spontaneously.¹⁷ FEH is seldom associated with immunodeficiency or suppression of the immune system.¹⁸ In our case, the patient's immune status was normal. However, FEH is an oral manifestation of HIV infection, so it is the primary duty of clinicians to make an early diagnosis of the disease and to bear the probability of HIV infection in mind.¹⁹ In our case, the possibility of such infectious blood diseases has been eliminated with the blood tests.

FEH diagnosis is based on clinical, histopathological and HPV genotypes. It is important to make an early diagnosis of FEH, because there are more serious diseases which should be considered as differential diagnosis such as inflammatory fibrous hyperplasia, inflammatory papillary hyperplasia, verruciform xanthoma, verrucous carcinoma, Cowden's disease, condyloma acuminatum and focal dermal hypoplasia syndrome.^{4,14} The first three types of lesions mentioned above

are reactive lesions. Therefore, an irritant agent must be detected as an indication of the presence of lesions. In our case, no irritant factor has been identified like removable prosthesis or malocclusion which can cause occlusal trauma. Verrucous carcinoma is a neoplasia of a different age group with epidemiological features typically found in oral carcinomas. Cowden's disease fibroepithelial polyps, which indicate characteristics of an older age group, have more consistent, less mobile and different intraoral topography.^{20,21}

Condyloma acuminatum is important for differential diagnosis because the clinical appearance of isolated lesions is similar for both diseases, as they are both HPV-derived.²² Nevertheless, the medical history of the patient is very useful for differential diagnosis. In this case, FEH lesions were more flat and numerous than HPV lesions. In addition, the location of FEH lesions (lip, tongue, and buccal mucosa) is very characteristic.⁴ Considering the age of the patient, medical history, blood tests, cytological examinations, and the clinical appearance of the lesions, FEH was considered as a preliminary diagnosis.

The lesions are removed with a scalpel only if they are exposed to occlusal trauma during mouth function or if the patient has requested the removal upon aesthetic concerns.^{5,15} Other treatment options include cryotherapy, electrocoagulation, laser, chemical agents such as retinoic acid, and immunostimulants such as interferon.^{15,23} In our case, the excision was performed with the help of a diode laser, because primary closure of the lesion would not be possible to after excision with a scalpel and also using diode laser could provide an easier hemorrhage control after the excision.

Recurrence is not predictable, therefore,

follow-up of patients is essential. When the symptoms of the disease recur, it is uncertain whether there is a new infection or it is caused by a viral delay or the weak immune system of the patient.¹⁰ The patient in this case was followed up for 24 months and no recurrence occurred during this period. Yet, the patient should be monitored further.

REFERENCES

- [1] Archard HO, Heck JW, Stanley HR. Focal Epithelial Hyperplasia: An Unusual Oral Mucosal Lesion Found in Indian Children. *Oral Surg Oral Med Oral Pathol.* 1965;20:201-12.
- [2] Liu N, Li Y, Zhou Y, Zeng X. Focal epithelial hyperplasia (Heck's disease) in two Chinese females. *Int J Oral Maxillofac Surg.* 2012;41:1001-4.
- [3] Ozden B, Gunduz K, Gunhan O, Ozden FO. A Case Report of Focal Epithelial Hyperplasia (Heck's disease) with PCR Detection of Human Papillomavirus. *J Maxillofac Oral Surg.* 2011;10:357-60.
- [4] Borborema-Santos CM, Castro MM, Santos PJ, Talhari S, Astolfi-Filho S. Oral focal epithelial hyperplasia: report of five cases. *Braz Dent J.* 2006;17:79-82.
- [5] Flaitz CM. Focal epithelial hyperplasia: a multifocal oral human papillomavirus infection. *Pediatr Dent.* 2000;22:153-4.
- [6] Pfister H, Hettich I, Runne U, Gissmann L, Chalf GN. Characterization of human papillomavirus type 13 from focal epithelial hyperplasia Heck lesions. *J Virol.* 1983;47:363-6.
- [7] Beaudenon S, Praetorius F, Kremsdorf D, Lutzner M, Worsaae N, Pehau-Arnaudet G, et al. A new type of human papillomavirus associated with oral focal epithelial hyperplasia. *J Invest Dermatol.* 1987;88:130-5.

- [8] Said AK, Leao JC, Fedele S, Porter SR. Focal epithelial hyperplasia - an update. *J Oral Pathol Med.* 2013;42:435-42. with focal epithelial hyperplasia: a case-control study. *J Clin Virol.* 2006;37:21-6.
- [9] Dos Santos-Pinto L, Giro EM, Pansani CA, Ferrari J, Massucato EM, Spolidorio LC. An uncommon focal epithelial hyperplasia manifestation. *J Dent Child (Chic).* 2009;76:233-6.
- [10] Castro TP, Bussoloti Filho I. Prevalence of human papillomavirus (HPV) in oral cavity and oropharynx. *Braz J Otorhinolaryngol.* 2006;72:272-82.
- [11] Gonzalez LV, Gaviria AM, Sanclemente G, Rady P, Tying SK, Carlos R, et al. Clinical, histopathological and virological findings in patients with focal epithelial hyperplasia from Colombia. *Int J Dermatol.* 2005;44:274-9.
- [12] Morrow DJ, Sandhu HS, Daley TD. Focal epithelial hyperplasia (Heck's disease) with generalized lesions of the gingiva. A case report. *J Periodontol.* 1993;64:63-5.
- [13] Ledesma-Montes C, Vega-Memije E, Garces-Ortiz M, Cardiel-Nieves M, Juarez-Luna C. Multifocal epithelial hyperplasia. Report of nine cases. *Med Oral Patol Oral Cir Bucal.* 2005;10:394-401.
- [14] Terezhalmay GT, Riley CK, Moore WS. Focal epithelial hyperplasia (Heck's disease). *Quintessence Int.* 2001;32:664-5.
- [15] Martins WD, de Lima AA, Vieira S. Focal epithelial hyperplasia (Heck's disease): report of a case in a girl of Brazilian Indian descent. *Int J Paediatr Dent.* 2006;16:65-8.
- [16] Jayasooriya PR, Abeyratne S, Ranasinghe AW, Tilakaratne WM. Focal epithelial hyperplasia (Heck's disease): report of two cases with PCR detection of human papillomavirus DNA. *Oral Dis.* 2004;10:240-3.
- [17] Cuberos V, Perez J, Lopez CJ, Castro F, Gonzalez LV, Correa LA, et al. Molecular and serological evidence of the epidemiological association of HPV 13
- [18] Steinhoff M, Metze D, Stockfleth E, Luger TA. Successful topical treatment of focal epithelial hyperplasia (Heck's disease) with interferon-beta. *Br J Dermatol.* 2001;144:1067-9.
- [19] Puriene A, Rimkevicius A, Gaigalas M. Focal epithelial hyperplasia: Case report. *Stomatologija.* 2011;13:102-4.
- [20] Reddy KV, Anusha A, Maloth KN, Sunitha K, Thakur M. Mucocutaneous manifestations of Cowden's syndrome. *Indian Dermatol Online J.* 2016;7:512-5.
- [21] Wright DD, Whitney J. Multiple hamartoma syndrome (Cowden's syndrome): case report and literature review. *Gen Dent.* 2006;54:417-9.
- [22] Pringle GA. The role of human papillomavirus in oral disease. *Dent Clin North Am.* 2014;58:385-99.
- [23] Durso BC, Pinto JM, Jorge J, Jr., de Almeida OP. Extensive focal epithelial hyperplasia: case report. *J Can Dent Assoc.* 2005;71:769-71.