




Aydın Dental Journal

Journal homepage: <http://dergipark.ulakbim.gov.tr/adj>



DOUBLE INVERTED MESIODENSES DIAGNOSED USING CBCT: AN EXCEPTIONAL ENTITY

DergiPark
AKADEMİK

Mehmet Ali ELÇİN¹, Gizem ÇOLAKOĞLU¹, Sercan KÜÇÜKKURT²

ABSTRACT

Mesiodens are tooth-like structures which occur in maxillary midline and have the major ratio of the supernumerary teeth. They are related to several syndromes, however may occur on healthy individuals, as well. They may be unerupted or erupted, in vertical, horizontal or inverted positions. They may lead to several complications such as root resorption of adjacent teeth, crowding, diastema and cyst formation whereas they may remain both asymptotically and unnoticed for a lifetime. Unerupted mesiodens are needed to be extracted if they cause any complications. However, unnecessary extractions of asymptomatic mesiodens should be avoided, considering possible damages on adjacent teeth and anatomic structures. In routine dental practice, mesiodens may be misdiagnosed due to the using of two dimensional radiographies. Nowadays, by means of three dimensional imaging methods such as CBCT, the morphology, location, relationship with anatomical structures of mesiodens and any pathology related with them can be identified precisely. Therefore, it can be easier to decide whether a surgical operation is needed in terms of profit/loss balance. The aim of this case report is to present a double-inverted mesiodens diagnosed using CBCT in a 61-year-old female patient, which reported in a small number of cases in the literature.

Keywords: Mesiodens, Inverted tooth, Supernumerary tooth, CBCT

ÖZET

Mesiodensler maksilla orta hat bölgesinde oluşan sünnümerer dişlerin en büyük oranını oluşturan diş benzeri yapılardır. Birçok sendromla ilişkili olabildiği gibi sağlıklı bireylerde de ortaya çıkabilmektedir. Gömülü veya sürmüş şekilde, vertikal, horizontal ya da inverted pozisyonda olabilirler. Komşu dişlerde kök rezorpsiyonu, çapaşıklık, diastema, kist oluşumu gibi birçok komplikasyona sebep olabilirken hayat boyu asemptomatik ve fark edilmeden de kalabilirler. Gömülü mesiodensler bir komplikasyona sebep oluyorsa çekilmeleri gerekmektedir. Diğer yönden semptomsuz mesiodenslerin gereksiz çekimlerinden ise operasyon sırasında komşu dişler ve anatomik yapılarda oluşabilecek zararlar düşünülerek kaçınılmalıdır. Rutin dental pratikte iki boyutlu görüntüleme yöntemleri tercih edildiği için mesiodensler her zaman teşhis edilemeyebilirler. Günümüzde CBCT gibi 3 boyutlu görüntüleme teknikleri sayesinde detaylı morfolojileri, konumları, anatomik oluşumlarla ilişkileri ve herhangi bir patoloji oluşturup oluşturmadıkları gibi faktörler net olarak tespit edilebilmektedir. Böylece cerrahi müdahale yapıp yapılmayacağına kar-zarar dengesi açısından daha kolay karar verilebilir. Bu olgu sunumunda literatürde oldukça az sayıda rapor edilmiş olan ve 61 yaşındaki bayan hastada CBCT sayesinde tespit edilebilmiş çift inverted mesiodens vakası rapor edilmektedir.

Anahtar Kelimeler: Mesiodens, Inverted dişler, Sünnümere dişler, Konik ışınlı bilgisayarlı tomografi

¹ Istanbul Aydın Üniversitesi Diş Hekimliği Fakültesi, Ağız, Diş ve Çene Radyolojisi ABD

² Istanbul Aydın Üniversitesi Diş Hekimliği Fakültesi, Ağız, Diş ve Çene Cerrahisi ABD

INTRODUCTION

Supernumerary teeth are a relatively common odontogenesis anomaly, which usually represents excess tooth formation.¹ They may be single or more than one, one-sided or double-sided, erupted or unerupted and may be seen in maxilla and mandible.² Mesiodens teeth, which is considered to be the most common type of supernumerary teeth in the literature, refer to an excessive number of teeth in the maxillary midline, mostly unerupted between maxillary incisors.^{2,3} Mesiodensses may be related to various craniofacial disorders/syndromes such as cleft lip, cleft palate and cleidocranial dysostosis and less often Gardner syndrome or chondroectodermal dysplasia. However, they may be encountered on healthy individuals, as well. Mesiodensses may be unerupted or erupted. They may remain stable without any clinical symptoms. Besides, they may cause complications such as; non-eruption or late eruption of adjacent teeth, crowding, ectopic eruption, diastema, eruption into nasal cavity, bone defects due to odontogenic cyst formation, pain, swelling and root resorption on adjacent teeth.^{4,5}

Unerupted mesiodensses may be detected with commonly used conventional radiographic methods such as orthopantomography, occlusal and periapical radiographies. Nevertheless, in some cases, they may not be detected when 2D radiographies do not provide clear display in maxillary midline.^{5,6} In order to overcome the restrictions of conventional radiographic methods, cone beam computed tomography (CBCT), which provides more detailed and correct evaluations, may be used. Moreover, by means of CBCT these structures can be detected more often.^{3,7,8}

In this case report, two asymptomatic inverted

mesiodensses which perforate the base of the nasal cavity in a 61 year-old female patient are presented. According to our knowledge, since the case of two invert positioned mesiodensses on a single patient has only been reported twice^{9,10} until now, our case may be accepted as an extremely rare one.

CASE REPORT

61 year-old female patient was referred to our faculty because of unidentified radiopaque areas located in the maxillary midline region detected on the radiographic examination (Fig.1).

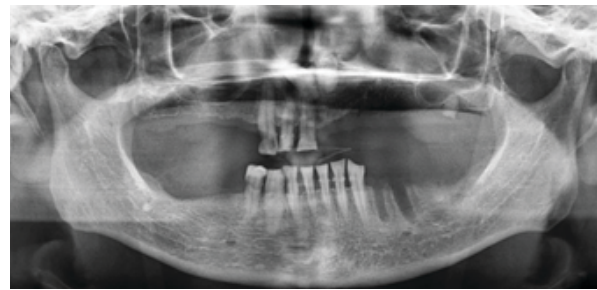


Figure 1. Orthopantomography of the patient showing radiopaque formations in the maxillary midline

The patient was systemically healthy. She had no clinical complaint and also no finding by inspection and palpation in the related region. Only the abrasions on maxillary right central incisor and canine, caused by the removable denture was found. The patient stated that she had no missing tooth in her denture, her teeth had been extracted due to the periodontal problems and tooth decays. However during her youth there had been crowding causing aesthetic problems particularly on anterior maxilla.

CBCT imaging (3D Accuitomo 170, J. Morita, Kyoto, Japan) using 250 µm voxel size with

140x100 cm field of view (FOV), 90 kV, 5mA and 30.8 sec. was performed in order to evaluate the region more detailed because it was not possible to diagnose the radiopaque formations on conventional radiographs. On CBCT, two microdontic inverted mesiodens, one in the palatine of the right incisor, the other in the palatal section of the missing left incisor, were found. Perforation of the nasal cavity base was the only pathology detected by CBCT, no root resorption was observed for the present right central incisor tooth. Also mesiodens were not in contact with the teeth and were not related to the nasopalatal canal (Figure 2, 3).

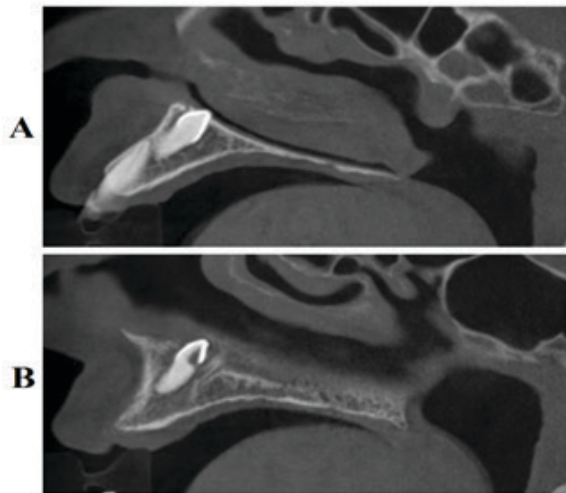


Figure 2. Sagittal CBCT sections of the patient A: Right mesiodens B: Left mesiodens perforating the base of nasal cavity.




Figure 3. Three dimensional reconstruction of CBCT images

Due to the asymptomatic course of mesiodens though perforating the nasal cavity base and the possibility of damaging the anatomic structures during the operation, not restricting new removable denture application and age of the patient, it was decided to follow the patient annually. After the prosthetic rehabilitation of the patient, she has been followed up over 2 years without complaint both clinically and radiologically.

DISCUSSION

Mesiodens are the most common form among supernumerary teeth. According to Mossaz et al.³ mesiodens form the 48.52% of supernumerary teeth. This finding is also supported by Fernandez Montenegro et al.¹¹ and Ferres-Padro et al.¹² as 46.9% and 53.16% respectively.

Mesiodens are observed rarely in mandibula and in primary dentition, more often in maxilla and in permanent dentition

and in general population as 0.15- 1.9 % at higher ratio in men.¹³ They may be vertical, horizontal and inverted. The frequency of inverted mesiodensses forms approximately 9-67% of all cases.^{14,15} In current literature, more than 278 single inverted mesiodensses have been reported until now.⁹ In literature most mesiodensses are in palatal position; yet, there are few cases which contact cortical bone of nasal base and walls of nasopalatine canal.^{3,6} Only 25% of the mesiodensses erupt in oral cavity spontaneously. Generally, they remain unerupted and asymptomatic and they are detected during routine radiographic examination.¹⁶ According to Nazif et al.¹⁷ 6% of them are located in labial position, 80% of them are located in palatal region and 14% of them are located between the roots of central incisors. Mossaz et al.³ reported that %20.5 of the mesiodensses contacted cortical bone of nasal base, 49% of them contacted nasopalatine canal. They split the ones which contact nasopalatine canal into three subcategories and 38.8% of them in an external contact with the canal, 8.2% of them perforate the canal and 2% of them located inside of the canal. In our case, both mesiodensses are in inverted position, unerupted in the palatal section of the both central incisors and perforating nasal base.

Mesiodensses commonly present a rudimentary morphology that has a cone-shaped crown, smaller than adjacent teeth. Additionally, there are some cases that they imitate a natural tooth shape. Root generally forms completely and may be curved or globular.^{9,11,12,18} In our case, mesiodensses were microdontic but they had a complete root development.

Two dimensional imaging methods such as orthopantomography can be performed in the diagnosis of mesiodensse. However,

orthopantomography is disadvantageous because the structures outside of the focus particularly in anterior section, may be superimposed by other anatomic structures. Therefore it will be impossible to display the anterior region in detail. Also occlusal radiographies may be used in order to evaluate the relationship of mesiodensse with adjacent teeth and anatomic structures and determine the exact location. However this imaging method may not be helpful in the base of nasal cavity. Nowadays, with the improvement of three dimensional imaging techniques, it is now possible to evaluate these structures more detailed using CBCT.^{3,6-8}

The most common complications caused by mesiodensses are the late eruption and rotation of maxillary permanent teeth whereas crowding, diastema, root dilatation of permanent teeth, cyst formation and eruption into nasal cavity are the more rare ones.¹⁹ In the cases with such complications, an comprehensive clinical and radiological evaluation is necessary in order to make a correct diagnosis. If mesiodensses cause any pathology, they should be extracted. Besides, if mesiodensses remain stable without symptoms and do not affect adjacent teeth or anatomic structures, they can be followed up periodically. Using CBCT helps the clinician to evaluate pathological changes or the relationship of mesiodensse with anatomic structures so clinician may determine whether to follow-up or extract the mesiodensse.^{3, 6, 11, 14} In our case, mesiodensses were asymptomatic and found as an incidental finding in the routine radiographic examination. The type of treatment was decided by evaluating CBCT images according to the profit and loss balance.

In this case report, one patient with two inverted mesiodensses which is rare in

literature, the diagnosis of these structures using CBCT and the significance of CBCT in detailed investigation and planning the treatment process are emphasized.

REFERENCES

- [1] Gallas MM, Garcia A. Retention of permanent incisors by mesiodens: a family affair. *Br Dent J.* 2000;188:63-4.
- [2] Parolia A, Kundabala M, Dahal M, Mohan M, Thomas MS. Management of supernumerary teeth. *J Conserv Dent.* 2011;14:221-4.
- [3] Mossaz J, Kloukos D, Pandis N, Suter VG, Katsaros C, Bornstein MM. Morphologic characteristics, location, and associated complications of maxillary and mandibular supernumerary teeth as evaluated using cone beam computed tomography. *Eur J Orthod.* 2014;36:708-18.
- [4] Rajab LD, Hamdan MA. Supernumerary teeth: review of the literature and a survey of 152 cases. *Int J Paediatr Dent.* 2002;12:244-54.
- [5] Russell KA, Folwarczna MA. Mesiodens--diagnosis and management of a common supernumerary tooth. *J Can Dent Assoc.* 2003;69:362-6.
- [6] Aoun G, Nasseh I. Mesiodens Within the Nasopalatine Canal: An Exceptional Entity. *Clin Pract.* 2016;6:903.
- [7] Kapila S, Conley RS, Harrell WE, Jr. The current status of cone beam computed tomography imaging in orthodontics. *Dentomaxillofac Radiol.* 2011;40:24-34.
- [8] Agrawal JM, Agrawal MS, Nanjannawar LG, Parushetti AD. CBCT in orthodontics: the wave of future. *J Contemp Dent Pract.* 2013;14:153-7.
- [9] Canoglu E, Er N, Cehreli ZC. Double inverted mesiodentes: report of an unusual case. *Eur J Dent.* 2009;3:219-23.
- [10] Dinkar AD, Dawasaz AA, Shenoy S. Dentigerous cyst associated with multiple mesiodens: a case report. *J Indian Soc Pedod Prev Dent.* 2007;25:56-9.
- [11] Fernandez Montenegro P, Valmaseda Castellon E, Berini Aytes L, Gay Escoda C. Retrospective study of 145 supernumerary teeth. *Med Oral Patol Oral Cir Bucal.* 2006;11:E339-44.
- [12] Ferres-Padro E, Prats-Armengol J, Ferres-Amat E. A descriptive study of 113 unerupted supernumerary teeth in 79 pediatric patients in Barcelona. *Med Oral Patol Oral Cir Bucal.* 2009;14:E146-52.
- [13] Van Buggenhout G, Bailleul-Forestier I. Mesiodens. *Eur J Med Genet.* 2008;51:178-81.
- [14] Asami JI, Shibata Y, Yanagi Y, Hisatomi M, Matsuzaki H, Konouchi H, et al. Radiographic examination of mesiodens and their associated complications. *Dentomaxillofac Radiol.* 2004;33:125-7.
- [15] Ersin NK, Candan U, Alpoz AR, Akay C. Mesiodens in primary, mixed and permanent dentitions: a clinical and radiographic study. *J Clin Pediatr Dent.* 2004;28:295-8.
- [16] Hattab FN, Yassin OM, Rawashdeh MA. Supernumerary teeth: report of three cases and review of the literature. *ASDC J Dent Child.* 1994;61:382-93.
- [17] Nazif MM, Ruffalo RC, Zullo T. Impacted supernumerary teeth: a survey of 50 cases. *J Am Dent Assoc.* 1983;106:201-4.
- [18] Giancotti A, Grazzini F, De Dominicis F, Romanini G, Arcuri C. Multidisciplinary evaluation and clinical management of mesiodens. *J Clin Pediatr Dent.* 2002;26:233-7.
- [19] Hyun HK, Lee SJ, Lee SH, Hahn SH, Kim JW. Clinical characteristics and complications associated with mesiodentes. *J Oral Maxillofac Surg.* 2009;67:2639-43.