



# Aydın Dental Journal

Journal homepage: <http://dergipark.ulakbim.gov.tr/adj>



## ***IS THE HYALURONIC ACID BENEFICAL FOR THE BONE HEALING IN DEFECTS OF CRITICAL SIZE IN ANGULUS MANDIBLE AREA?: AN EXPERIMENTAL STUDY***

**DergiPark**  
AKADEMİK

*Aykut KAHVECİ PhD. DDS<sup>1</sup>, Prof. Dr. Mustafa ÖZTÜRK<sup>1</sup>, Sibel Elif GÜLTEKİN PhD DDS<sup>1</sup>*

### **ABSTRACT**

This study was aimed to evaluate the effect of hyaluronic acid on bone healing in an angulus mandible defect of a rabbit. Twenty-four New Zealand white male rabbits were used in this study. Bilateral 9x5 mm defects were made on the left and right angulus mandible of each rabbit. The left defect was filled with hyaluronic acid gel (experimental one), while the right defect was left for normal healing (control one). The rabbits were randomly divided and sacrificed during the 1<sup>st</sup>, 2<sup>nd</sup>, 3<sup>rd</sup> and 4<sup>th</sup> weeks postoperatively. The defect sites were evaluated by histologic analyses for bone healing at all healing interval. According

to the histopathological examination results, there was statistically significant difference in the amount of new bone formation between hyaluronic acid and control groups ( $P < 0.05$ ). On the 21<sup>st</sup> and 28<sup>th</sup> days, the amount of new bone formation was higher in hyaluronic acid groups. The inflammation scores were statistically lower in the hyaluronic acid group than the control group on the 28<sup>th</sup> day. Local injections of hyaluronic acid in mandibular critical size bone defect may improve new bone formation. Hyaluronic acid could be taken as a graft material for bone defects.

**Keywords:** *Bone healing, hyaluronic acid, rabbits*

<sup>1</sup> Gazi University Faculty of Dentistry Department of Oral and Maxillofacial Surgery

## **MANDİBULA ANGULUS BÖLGESİNDEKİ KRİTİK BOYUTLARDAKİ KEMİK DEFEKTLERİNİN İYİLEŞMESİNDE HİYALÜRONİK ASİT FAYDALI MI? BİR DENEYSEL ÇALIŞMA**

*Aykut KAHVECİ PhD. DDS<sup>1</sup>, Professor Mustafa ÖZTÜRK<sup>1</sup>, Sibel Elif GÜLTEKİN PhD DDS<sup>1</sup>*

### **ÖZ**

Bu çalışmada, hyalüronik asidin bir tavşanın angulus mandibulasında oluşturulan defektin kemik iyileşmesi üzerindeki etkisinin değerlendirilmesi amaçlanmıştır. Bu amaçla yirmi dört Yeni Zelanda beyaz erkek tavşanı kullanılmıştır. Sol ve sağ angulus mandibulada her tavşan için iki taraflı 9x5 mm defekt yaratılmıştır. Sol defekt hyaluronik asit jeli (deney grubu) ile doldurulurken, sağ defekt normal iyileşme için bırakılmıştır (kontrol grubu). Tavşanlar rastgele bölünmüş ve operasyon sonrası 1, 2, 3 ve 4 haftada sakrifiye edilmiştir. Defekt bölgeleri, tüm iyileşme aralıklarında kemik iyileşmesi için histolojik analizlerle değerlendirilmiştir. Histopatolojik

inceleme sonuçlarına göre hyaluronik asit ve kontrol grupları arasında yeni kemik oluşum miktarında istatistiksel olarak anlamlı fark bulunmuştur ( $P<0.05$ ). 21. ve 28. günlerde, hyaluronik asit gruplarında yeni kemik oluşum miktarının daha yüksek olduğu tespit edilmiştir. Enflamasyon skorları 28. günde hyaluronik asit grubunda, kontrol grubundan istatistiksel olarak düşük bulunmuştur. Mandibular kritik kemik defektlerinde lokal hyaluronik asit enjeksiyonları yeni kemik oluşumunu hızlandırarak iyileştirebilir. Hyaluronik asit kemik defektleri için greft materyali olarak kullanılabilir.

**Anahtar Kelimeler:** Kemik iyileşmesi, hyaluronik asit, tavşan

---

<sup>1</sup> Gazi Üniversitesi Dış Hekimliği Fakültesi, Ağız Diş ve Çene Cerrahisi

## INTRODUCTION

The treatment of bone reconstruction is a prominent area of maxillofacial surgery. Various surgical techniques has been used for treating bone defects which includes bone grafts, synthetic bone substitutes, and extracellular matrix elements.<sup>1,2</sup> These can be achieved in the treatment of small-to-moderate-sized defects whereas the success of treatment in large bone defects remains as a challenge. Therefore, the reconstruction of the critical sized defects by different graft materials still has value to be investigated in the field. Hyaluronic acid (HA) (synonyms-hyaluronan, hyaluronate) is versatile, consisting of repeating units of ( $\beta$ , 1-4) glucuronic acid-( $\beta$ , -3)-N-acetyl glucosamine, polymorphic and linear non-sulfated glycosaminoglycan (GAG). Hyaluronic acid is found in every human body and tissue fluid, in significant quantities in the skin (epidermis and dermis), central nervous system and brain.<sup>3,4</sup> Hyaluronic acid is playing an important role in wound healing. In inflammatory phase, HA binds to fibrinogen to commence clotting pathway, allows inflammatory cell migration. HA deposition precedes leukocyte response.<sup>4,5</sup> In proliferation phase, epithelial keratinocytes migrate from the wound edges toward the center (a process initiated within the first 24 h of injury), helping to seal the defect, prevent fluid loss and exclude infection.<sup>6</sup> Although several studies have examined the use of hyaluronic acid in bone healing (symphysis and corpus mandible), none has examined the healing at the angulus mandible defects. Moreover, there is no study available on the critical sized defects in the mandible angulus region. Therefore, we aimed to evaluate the response of hyalurnic acid treatment in large bone defects as a potential supportive regeneration material.

## MATERIALS AND METHODS

### Surgical Procedure

This study, which includes living animals, was approved by the Local Ethics Committee of Gazi University. Twenty-four adult male, 3-3,5 kg New Zealand White rabbits were randomly divided into 4 groups which had bilateral bone defects on the angular mandible performed in a standard fashion by the same surgeons. Institutional guidelines for the care and treatment of the laboratory animals were followed. Rabbits were housed 1 per cage, and food and water were available ad libitum. Following the appropriate intramuscular anesthesia with xylazine (5 to 7 mg/kg) and ketamine (35 to 45 mg/kg), during surgery, supplemental sedation was administered when needed. After the administration of local anesthesia, the mandible was shaved and prepped with Betadine solution for disinfecting the surgical site in each animal. An extra-oral skin incision was made on the angular process and 0,5 cm under the inferior border of the mandible bilaterally. Dissection was carried down through the subcutaneous and muscle layers to the periosteum. After exposing the masseter muscle, subperiosteal elevation of the muscle's detachment was performed both buccally and lingually. The periosteum was then incised and reflected to expose the angular mandible. Under continuous saline irrigation, a rotating trephine burr was used to create circular, bilateral defects standardized at 9x5 mm angular mandible in each animal to form the control and experimental defects (figure 1a). This size has been reported to prevent spontaneous healing during an animal's lifetime. The left defect was filled with hyaluronic acid gel (Hyadent, Bioscience GmbH-Germany) as the experimental defect (figure 1b). The right defect was not filled with any material other than blood clot and normal wound healing was allowed in the control group. The soft tissues were reapproximated and closed in a layered fashion with interrupted 4-0 resorbable polyglactin sutures and skin staples.

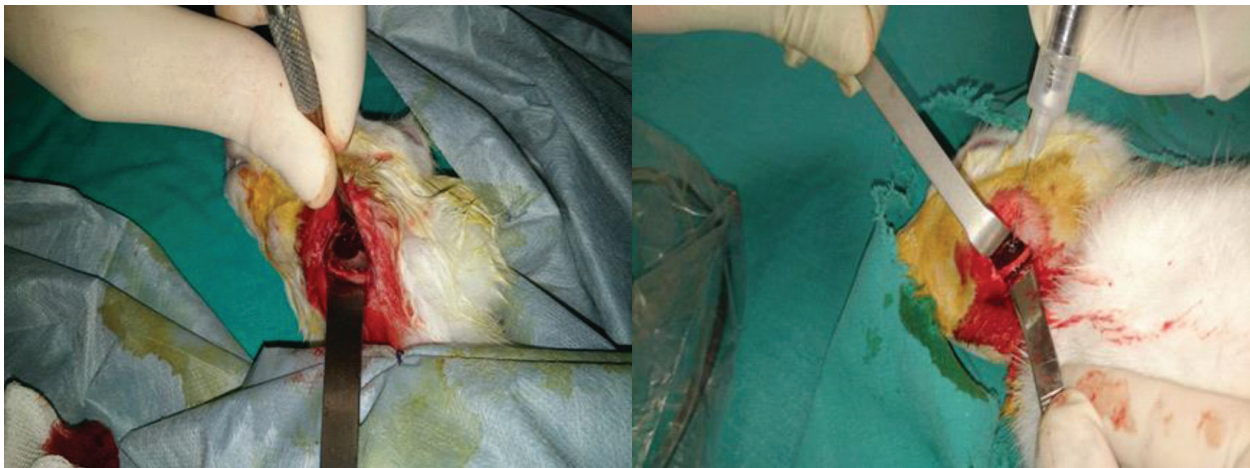


Figure 1: Intraoperative photograph, **a**: 9 mm diameter circular bone defect, **b**: Local injections of hyaluronic acid in bone defect area.

Animals were sacrificed in 1<sup>st</sup>, 2<sup>nd</sup>, 3<sup>rd</sup> and 4<sup>th</sup> weeks. Six animals were sacrificed per week. The mandibles were harvested en bloc.

### **Histopathology and Histomorphometric Analysis**

All histological procedures and evaluations were carried out at the Department of Oral Pathology, Faculty of Dentistry, Gazi University. Block biopsies that are composed of bone surrounded by soft tissue were fixed with 10% buffered formalin solution. All materials were decalcified with 10% hydrochloric acid (Shandon™ TBD-1™ Decalcifier, Thermo, UK) for 2 days, which was followed by washing under tap water overnight.

After dehydration and paraffin embedding, the specimens were serially cut into 4- $\mu$ m-thick sections and stained with routine haematoxylin and eosin (H&E). Histomorphometric analysis was performed to quantify the relative amounts of the newly formed tissue types in each defect under light microscopy (Nikon THR, Japan) by using semi-quantitative method with an ocular grid at 200x magnification. The following

parameters were assessed in the defect area; Newly formed bone (NFB 2), Newly formed connective tissue (CT 3), The density of inflammation. The percentages of the values were also obtained in relation to the total defect area. Newly Formed Bone (NFB%) =  $\frac{\text{New bone area}}{\text{Total defect area}} \times 100$  (NB%). Connective tissue (CT%) =  $\frac{\text{connective tissue area}}{\text{Total defect area}} \times 100$ .

Inflammation was evaluated by counting inflammatory cells at 40x magnification and scored on a four-grade scale: grade 0: no inflammation; grade 1: <15 cells per field; grade 2: 15 to 50 cells per field; and grade 3: >50 cells per field, as described earlier.<sup>7</sup>

### **Statistical Analysis**

All data were analyzed with the statistical package for SPSS 20.0. of data. Kruskal-Wallis and Anova variant analyses were used to identify differences among the group scores. The boxplot graphs were used to detect significant differences within each group. Statistical significance was accepted at  $P < 0.05$ .



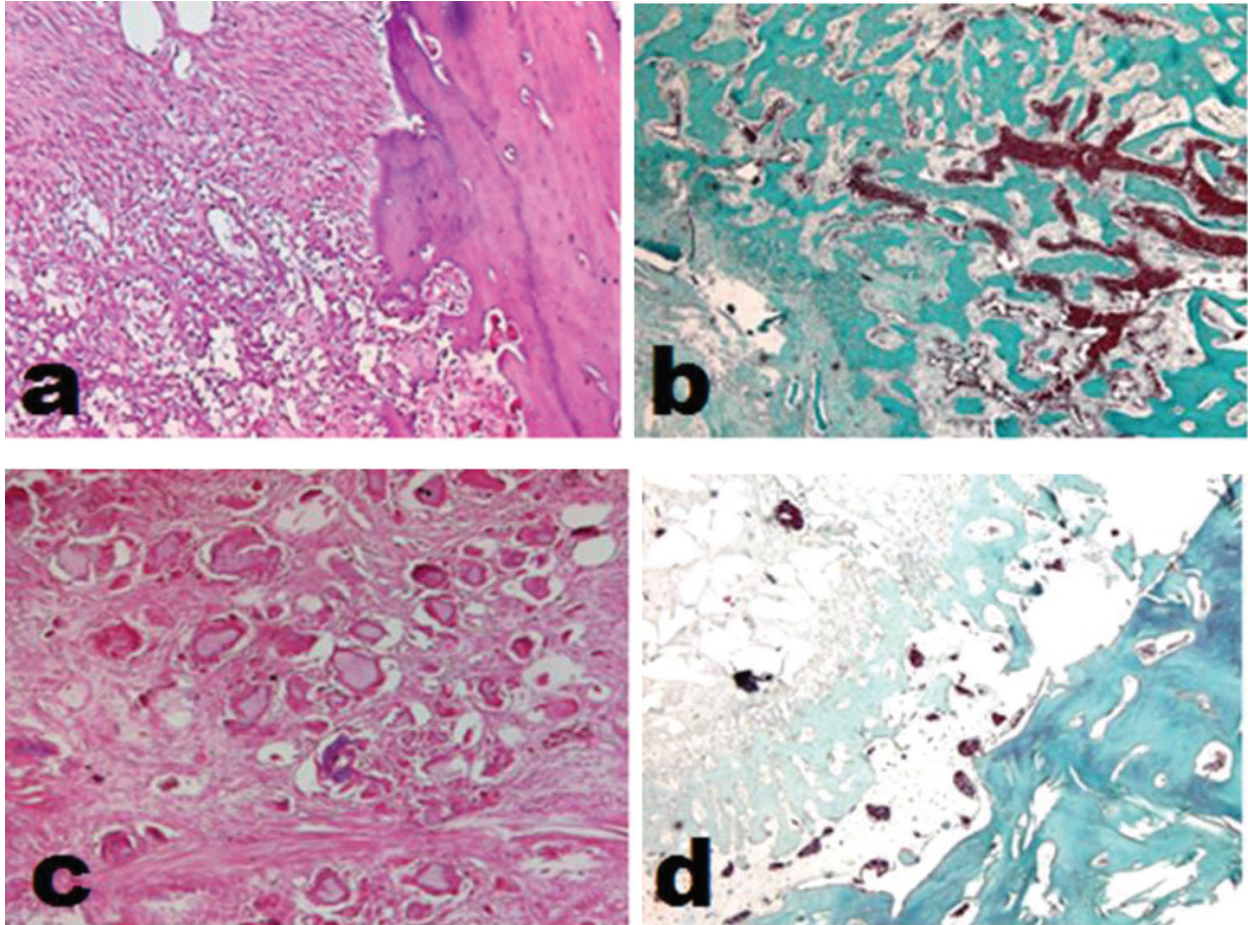


Figure 2: histologic analyses of experimental groups, **a**: on 7<sup>th</sup> day (tricom), **b**: on 14<sup>th</sup> day (alcian blue pas), **c**: on 21<sup>st</sup> day (hematoxylin-eosin), **d**: on 28<sup>th</sup> day (hematoxylin-eosin).

#### On day 7

All defects were mainly filled with well vascularized, highly cellular newly formed connective tissue and a few newly formed bone islands and calcified spherules in both control and experimental groups. Prominent hemorrhage and dense inflammation on connective tissue were seen in all samples. Remnants of hyaluronic acid gel were embedded within the newly formed connective tissue in all experimental defects. The existence of multinucleated giant cells underneath the defect wall was observed in 2 specimens of the experimental group whilst one subject had similar appearance in control group (Figure 1a-2a). There was no sign of necrosis in both groups.

#### On day 14

Both in control and experimental groups, defect areas were filled with fibrous connective tissue with fine collagen bundles and osteoid trabecules. The amount of newly formed bone trabecules were higher than the groups on 7 days. In experimental defects hyaluronic acid gel spaces, and irregular calcification in the connective tissue were observed (Fig.2b). Although new bone formation was generally seen in an immature character, in some areas it was observed to have taken part in mature form.

In control defects, congestion was more prominent between the anastomosing bone trabecules than in experimental group (Fig. 3b). There was mild mono-nuclear inflammatory infiltration in both groups (Table 3).



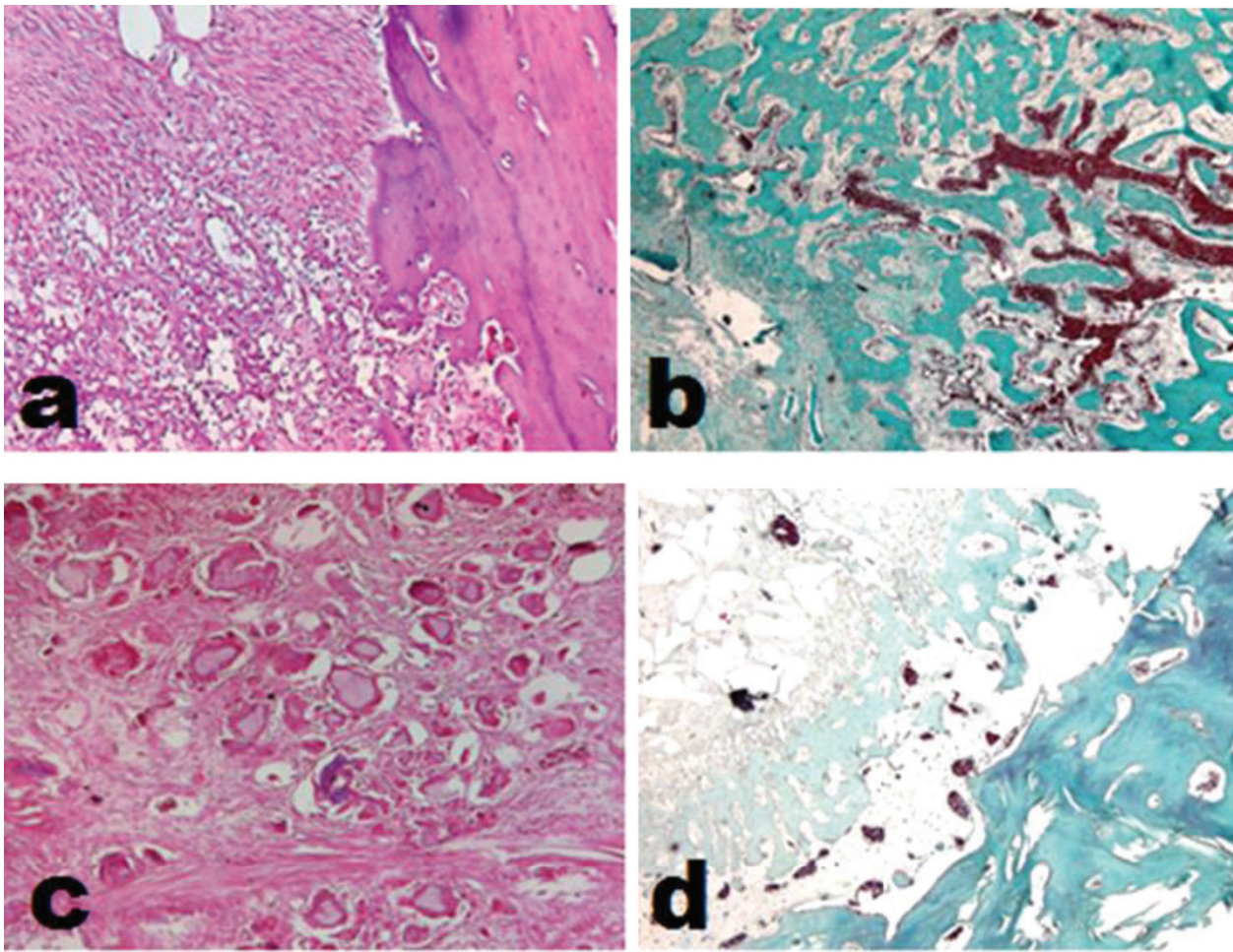


Figure 3: Histologic analyses of control groups, **a:** on 7<sup>th</sup> day (hematoxylin-eosin), **b:** on 14<sup>th</sup> day (trichrom), on 21<sup>st</sup> day (hematoxylin-eosin), on 28<sup>th</sup> day (trichrom).

#### **On day 21**

In all samples, fibrous connective tissue, new bone formation and calcified structure were observed. The fibroblast cells, that are the constituent of connective tissues, were more mature and their collagen bundle were denser than 7<sup>th</sup> and 14<sup>th</sup> days experimental groups (Fig 2 and 3c).

In control group, abscess formation was seen in one sample. Otherwise mild mono-nuclear inflammation was prominent in all defects of both groups.

#### **On day 28**

In the experimental defects evident new bone formation, host bone and less fibrocellular connective tissue were observed (Fig.2d). Bone tissue was more compact and the defect edges towards the middle followed the anastomosis style.

New bone formation, connective tissue and host bone were observed in the defect area of the control group (Fig.3d). In one sample, common mononuclear inflammatory cell infiltration was found.

### Histomorphometric analysis

Table 1 displays the mean values of new bone formation in percentage of experimental group defects. The increase of bone formation was seen in both experimental and control group defects when compared to 7-21 days ( $P < 0.005$ ). The experimental group defects had higher amount of new bone formation on days 7 and 28 than those in control group. The statistically significant difference was seen on day 28 between the two groups ( $P < 0.005$ ), (Table 2).

There were no statistical differences in the inflammation scores of both groups (Table 3).

Table 1: The percentage of new bone formation in experimental groups

Days	Maximum (%)	Minimum (%)	Mean±std. (%)
7	43,30	13,30	22,7±11,33
14	51,60	23,30	34,13±11,50*
21	58,30	21,60	38,56±16,14**
28	61,60	12,50	44,26±16,95*

\* $P < 0.01$  \*\* $P < 0.05$

Table 2: The percentage of new bone formation in control groups

Days	Maximum (%)	Minimum (%)	Mean±std. (%)
7	38,30	5,00	19,70±12,30
14	55,00	29,30	9,73±10,42
21	66,60	18,30	48,56±16,02
28	66,60	13,30	40,13±21,51

Table 3: Inflammation score experimental and control groups

Days	7	14	21	28
Experimental n=24	2	1	1	1
Control n=24	2.5	1	1	1

### DISCUSSION

The purpose of this study was to evaluate the effects of hyaluronic acid on bone healing in a critical size angulus mandible defect model. Critical size defect healing is one of the issues in maxillofacial surgery that is not completely resolved yet. Researchers are investigating the factors that affect the critical size bone defect healing and accelerate the process. When bone loss exceeds critical dimension, a spontaneous healing is usually not expected.<sup>8</sup> In the present study, complete closure of the control defect did not occur before 28 days after surgery, which indicates that the used 9 mm defect fulfilled the requirements for a critical size defect as reported in other studies.<sup>9</sup>

Hyaluronic acid is a component of the extracellular matrix that stimulates migration, adhesion, proliferation and cell differentiation.<sup>10</sup> The hyaluronic acid used in this study is a commercially available cross-linked product. According to a previous study, the reticulated hyaluronic acid can demonstrate a better regenerative function compared to linear hyaluronic acid.<sup>11</sup>

The present study has demonstrated that hyaluronic acid gel was able to improve bone formation when used alone. The same results were obtained by Sadıkoğlu and et. al. in a histologic evaluation, where the hyaluronic acid was used alone.<sup>12</sup>

Histologic, histomorphometric and histochemical evaluations have shown that after receiving hyaluronic acid, angulus mandible critical size defect exhibits newly formed bone and little fibrous tissue.

## CONCLUSIONS

In the hyaluronic acid aided experimental groups, new bone formation and maturation values was the highest compared to control groups as seen in the provided results. Therefore, it can be said that hyaluronic acid stimulates new bone formation in the angulus mandible critical size defects.

## ACKNOWLEDGEMENTS

Experimental animal study, histologic, histomorphometric, histochemical evaluation and statistical analysis was supported by Gazi University.

## REFERENCES

- [1] Fillingham, Y. and J. Jacobs, Bone grafts and their substitutes. *Bone Joint J*, 2016. 98 (1 Supple A): p. 6-9.
- [2] Kinoshita, Y. and H. Maeda, Recent developments of functional scaffolds for craniomaxillofacial bone tissue engineering applications. *The Scientific World Journal*, 2013.
- [3] David-Raoudi, M., et al., Differential effects of hyaluronan and its fragments on fibroblasts: relation to wound healing. *Wound Repair and Regeneration*, 2008. 16 (2): p. 274-287.
- [4] Frenkel, J.S., The role of hyaluronan in wound healing. *International wound journal*, 2014. 11 (2): p. 159-163.
- [5] Aya, K.L. and R. Stern, Hyaluronan in wound healing: rediscovering a major player. *Wound repair and regeneration*, 2014. 22 (5):p. 579-593.
- [6] Monslow, J., et al., Wounding-induced synthesis of hyaluronic acid in organotypic epidermal cultures requires the release of heparin-binding egf and activation of the EGFR. *Journal of Investigative Dermatology*, 2009. 129 (8): p. 2046-2058.
- [7] Hirshberg, A., et al., The influence of inflammation on the polarization colors of collagen fibers in the wall of odontogenic keratocyst. *Oral oncology*, 2007. 43 (3):p. 278-282.
- [8] Hollinger, J.O. and J.C. Kleinschmidt, The critical size defect as an experimental model to test bone repair materials. *Journal of Craniofacial Surgery*, 1990. 1 (1): p. 60-68.
- [9] Thomaidis, V., et al., Comparative study of 5 different membranes for guided bone regeneration of rabbit mandibular defects beyond critical size. *Medical Science Monitor*, 2008. 14 (4): p. BR67-BR73.
- [10] Dechert, T.A., et al., Hyaluronan in human acute and chronic dermal wounds. *Wound Repair and Regeneration*, 2006. 14 (3): p. 252-258.
- [11] Aguado, E., et al.,  $\beta$ -TCP granules mixed with reticulated hyaluronic acid induce an increase in bone apposition. *Biomedical Materials*, 2013. 9 (1): p. 015001.
- [12] Sadikoglu, T., et al., Effect of hyaluronic acid on bone formation in the expanded interpremaxillary suture in rats. *Orthodontics & craniofacial research*, 2016. 19 (3): p. 154-161.