




Aydın Dental Journal

Journal homepage: <http://dergipark.ulakbim.gov.tr/adj>



ESTHETIC ZONE SPACE MANAGEMENT IN DENTAL IMPLANT TREATMENT IN CONJUNCTION WITH ORTHODONTIC TREATMENT

DergiPark
AKADEMİK

Nima Moharamnejad DMD, MD,¹

ABSTRACT

The optimal restoration of a single tooth in the aesthetic zone needs to be in harmony with the other teeth, smile line, lip position and offer a stable function for the patient. The adjacent orthodontic treatment may reduce the delivery time and provide a more optimal result

regarding the harmony of the adjacent teeth and soft tissues. This article presents a case report where adjacent orthodontic treatment enhances the final result.

Keywords: *Dental implant, orthodontic treatment, emergence profile, soft tissue management*

¹ Gazi University, Faculty of Dentistry, Department of Oral and Maxillofacial Surgery

ORTODONTİK TEDAVİ İLE BİRLİKTE UYGULANAN DENTAL İMPLANT TEDAVİSİNDE ESTETİK BÖLGEDE ALAN YÖNETİMİ

Dr. Öğr. Üyesi Nima Moharamnejad¹

ÖZ

Tek dişin estetik bölgede en uygun şekilde restorasyonu, diğer dişlere uyumlu, gülümseme çizgisi, dudak pozisyonu gerektirir ve hasta için stabil bir fonksiyon sunar. Eş zamanlı ortodontik tedavi, tedavi süresini kısaltmasının yanı sıra komşu dişleri ve yumuşak dokuları harmonize etmek için

en uygun sonucu sağlayabilir. Bu makalede, dental implant tedavisi sırasında komşu dişlere uygulanan ortodontik tedavinin, nihai estetik sonucu arttırdığı bir olgu sunulmaktadır.

Anahtar Kelimeler: Dental implant, ortodontik tedavi, çıkış profili, yumuşak doku yönetimi

¹ Gazi Üniversitesi, Diş Hekimliği Fakültesi, Ağız, Diş ve Çene Cerrahisi ABD

INTRODUCTION

The placement of a single implant in aesthetic zone is more challenging and the result is usually received with a high-expectation. There are many factors that dictate the ideal position of implant such as soft tissue, bone volume and adjacent teeth. Any defect could be reconstructed by augmentation or orthodontic developments. However, these methods have their own limitations. Some of these factors may not support each other and make the surgeon place the implant in a sub-ideal position. Since the implant treatment requires time, most of the patients do not remember their primary situation and demand higher results at delivery time. The provisionalization brings good connection to patient, practitioner and laboratory. The orthodontic treatment can optimize the delivery and this article presents a case where adjacent orthodontic treatment enhances the final result.

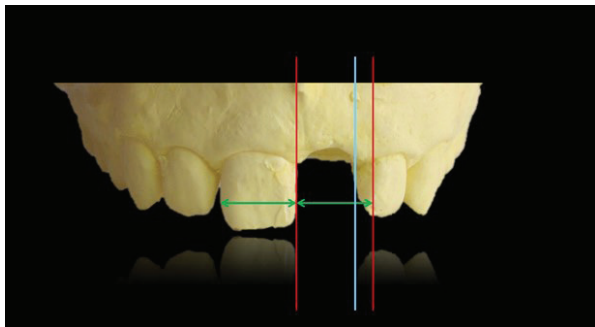


Figure 1: Diagnostic cast shows the required space for symmetrical restoration (red lines and green marks) and the available space is marked with a blue line

CASE REPORT

A 22 years old, healthy, non-smoker female presented for the restoration of the tooth number 21 that had received a dental implant

four months ago. Regarding her history, she had a trauma during childhood and mentioned the tooth being treated endodontically but that 4 months ago tooth fractured vertically. The tooth was extracted and the implant (C1 @ MIS - 5 mm width) was inserted immediately by another practitioner. However, it had not been provisionalized and patient did not resort to the edentulous area temporarily. The initial oral examination shows that the mid line is off. A diagnostic impression was taken and the assessment of this model shows that the available space mesiodistally was not symmetrical to the other incisor (Fig. 1). It is also noted that there is a spacing between number 12 and 11 and number 22 and 23 teeth. After discussing the treatment options with the patient, it was decided to orthodontically arrange the teeth to acquire the desired space for the implant restoration. Based on the primary cast, a temporary acrylic restoration was prepared and delivered. The teeth from number 22 to 13 were bracketed and a temporary mini implant was inserted between the teeth number 13 and 14. An opening coil were used in tooth 21 position and chain administer from mini implant serially to tooth 11 to segmentally close the right space (Fig. 2). No wire sequence was used. During the whole treatment, the SS 16 round well adapted and heat-treated wire were applied. Patient visited weekly and, in each visit, the temporary restoration contacts were adapted to the proximal tooth. The mid line offset was adjusted and a symmetrical space was gained in 6 weeks (Fig. 3). The final impression is taken and a screw type porcelain fused to metal crown delivered. The brackets were removed and the patient was put on retention for 2 months. The patient was satisfied with the result and has been since followed every 3 months.

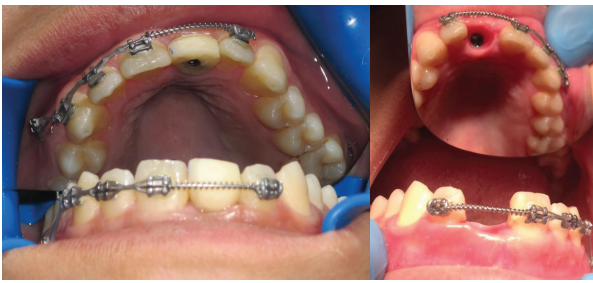


Figure 2: Final temporary restoration adjustment and soft tissue emergence

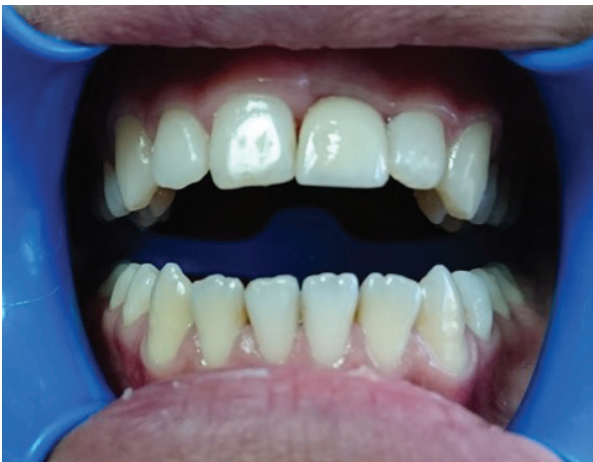

Figure 3: Final prosthetic delivery

DISCUSSION

Ideal placement of a dental implant is more likely to depend on the required and the available bone volume both vertically and horizontally. The single tooth implant supported restoration had the advantages of seeing the architecture of the adjacent tooth soft tissues, papilla and cemento-enamel junction to guide the surgeon for inserting the implant at very specific level bucco-lingual mesiodistally and apico-incisally. However, the tooth lost in the esthetic zone is usually associated with long term unsuccessful treatments which result with bone loss that compromises the implant insertion. The final result of this restoration

completely depends on the knowledge of the dentist regarding the limitations and the available techniques for site development otherwise the conventional techniques such as fixed partial prosthesis would be more reasonable.^{1,2} There are many indications to use the orthodontic adjacent treatment for the development of an implantation site. The history of trauma and fracture, periodontal treatment failure, non-restorable caries are among these indications.³ The extrusion with orthodontic forces, so called forced-eruption, is one of the acceptable methods. The main advantage of this method is predictability and controllability as the process requires. The rate of extrusion is usually about 1 or 2 mm per month with no more than 50 g force which require 1-month retention.^{2,4,6} The other benefit of this protocol is the movement of gingival attachment to the ideal coronal position. The animal models show that the amount of eruption in vertical movement is 80 percent of the attached gingiva and 90 percent of the free gingiva.⁷ The space management of the edentulous area is another adjacent orthodontic treatment. The movement of the tooth to the ideal site is aimed with respect to smile line, mid sagittal line and contra occlusion which are some of the indications of this treatment. The tooth movement adjacent to the edentulous area could result in reduction of bone height (%6-12) and bone width specially in anterior region.⁸ This kind of movement would not preserve the ridge more than 2 years and any bone intervention should be performed in this limitation of time or orthodontic spacing should be postponed for the implant placement. This may apply for the restoration of a missed tooth during childhood when the implant is placed after skeletal growth completion.⁹

CONCLUSION

Provisionalization of the restoration of a single tooth in the esthetic zone can provide a good judgment to the clinician as well as the patient and also it delivers better emergence profile to soft tissue which is required for good esthetic result.¹⁰

REFERENCES

- [1] Kois JC. Predictable single tooth peri-implant esthetics: five diagnostic keys. Compendium of continuing education in dentistry (Jamesburg, NJ: 1995). 2001; 22: 199-206; quiz 8.
- [2] Salama H, Salama M, Kelly J. The orthodontic-periodontal connection in implant site development. Pract Periodontics Aesthet Dent. 1996; 8: 923-32; quiz 34.
- [3] Mantzikos T, Shamus I. Forced eruption and implant site development: an osteophysiologic response. American journal of orthodontics and dentofacial orthopedics. 1999; 115: 583-91.
- [4] Kim SH, Tramontina VA, Papalexiou V, Luczyszyn SM. Orthodontic extrusion and implant site development using an interocclusal appliance for a severe mucogingival deformity: a clinical report. J Prosthet Dent. 2011; 105: 72-7.
- [5] Korayem M, Flores-Mir C, Nassar U, Olfert K. Implant site development by orthodontic extrusion. A systematic review. Angle Orthod. 2008; 78: 752-60.
- [6] Rose TP, Jivraj S, Chee W. The role of orthodontics in implant dentistry. Br Dent J. 2006; 201: 753-64.
- [7] Kajiya K, Murakami T, Yokota S. Gingival reactions after experimentally induced extrusion of the upper incisors in monkeys. Am J Orthod Dentofacial Orthop. 1993; 104: 36-47.
- [8] Uribe F, Chau V, Padala S, Neace WP, Cutrera A, Nanda R. Alveolar ridge width and height changes after orthodontic space opening in patients congenitally missing maxillary lateral incisors. Eur J Orthod. 2013; 35: 87-92.
- [9] Novackova S, Marek I, Kaminek M. Orthodontic tooth movement: bone formation and its stability over time. Am J Orthod Dentofacial Orthop. 2011; 139: 37-43.
- [10] De Rouck T, Collys K, Cosyn J. Single-tooth replacement in the anterior maxilla by means of immediate implantation and provisionalization: a review. Int J Oral Maxillofac Implants. 2008; 23: 897-904.